

# Quantifying proximal patellar tendon changes during adolescence in elite ballet dancers, a 2-year study

A. Rudavsky<sup>1</sup>  | J. Cook<sup>2</sup> | S. Docking<sup>2</sup> 

<sup>1</sup>Institute of Sports Medicine  
Copenhagen, Department of Orthopedic  
Surgery M, Bispebjerg Hospital and Center  
for Healthy Aging, Faculty of Health  
and Medical Sciences, University of  
Copenhagen, København, Denmark

<sup>2</sup>La Trobe Sport and Exercise Medicine  
Research Centre, La Trobe University,  
Melbourne, VIC, Australia

## Correspondence

Aliza Rudavsky, Department of Clinical  
Medicine, Bispebjerg-Frederiksberg  
Hospital - Bispebjerg, København, NV,  
Denmark.

Email: dsg351@alumni.ku.dk

Patellar tendon pathology appears to develop in young athletes. It is not known how this tendon develops through adolescence. This longitudinal study investigated proximal patellar tendon development during the adolescent growth spurt in young ballet dancers and identified whether puberty (estimated by maturity offset) had an effect on tendon development. Fifty two dancers (32 female and 20 male dancers, ages 11-18 at baseline) had ultrasound images of their tendons every 6 months for 2 years. Changes in tendon size (anterior-posterior diameter) on grayscale images and echogenicity, as quantified using ultrasound tissue characterization, were recorded each time. Maturity offset was calculated used to estimate peak height velocity (adolescent growth spurt). Maturity offset did not affect effect tendon composition before peak height velocity; however, after participants passed peak height velocity, maturity offset increased the composition of stable echopattern ( $P < .05$ ): a 4% differential increase in type I echopattern, indicative of normal tendon structure, and a decrease in type III echopattern (more disorganized echopattern) by 0.7% per year. Anterior-posterior thickness increased by 0.2 mm/y ( $P < .05$ ) measured 2 cm below the patella. Following peak height velocity, the proximal patellar tendon attachment increased in thickness and demonstrated a more stable echopattern representative of aligned fibrillar structure. Future research is required to further understand this normal maturation and the factors that support this process, with the aim of reducing the development of patellar tendon pathology in the adolescent jumping athlete.

## KEYWORDS

peak height velocity, tendon development, ultrasound tissue characterization

## 1 | INTRODUCTION

Tendinopathy refers to the clinical diagnosis of tendon pain and dysfunction, whereas tendon pathology is structural change within the tendon tissue, usually identified on ultrasound or MRI.<sup>1</sup> Lower limb tendinopathy and tendon pathology are seen in adolescents, with the incidence of symptoms increasing up to 18 years of age.<sup>2</sup> Pathology at the proximal attachment of the patellar tendon has been shown to increase the risk of developing pain (patellar tendinopathy (PT)),<sup>3-5</sup> commonly known as jumper's knee. PT is frequently observed in athletes of sports that involve high volumes of

jumping, such as basketball, volleyball, and dance. The prevalence of tendon pathology in adolescent basketball players (aged 14-18 years of age) is similar to the adult population (26% in adolescents compared to ~30% in adults<sup>4</sup>), suggesting that the normal tendon maturation during adolescence is disrupted leading to the development of tendon pathology, which may remain into adulthood.

Understanding of how the proximal patellar tendon matures has previously been based on the sparse literature about general tendon development, which indicates that tendons elongate and thicken at a rate proportional to the growth of their associated muscles and bones.<sup>6-8</sup> Recent studies have

investigated the patellar tendon and quadriceps muscle development and demonstrated that there is an imbalance between quadriceps and patellar tendon cross-sectional area (CSA) in adolescents compared to adults.<sup>9</sup> Mersmann et al demonstrated that while transitioning from early to late adolescence, the patellar tendon CSA and stiffness increased, as did tendon strength.<sup>10,11</sup> This evidence supports the hypothesis that adolescence is a critical time for tendon development.

The adolescent growth spurt during puberty is a period of rapid growth that may be a critical time for tendon maturation. Puberty can be quantified by measuring the peak growth of the adolescent growth spurt (peak height velocity (PHV)) that is typically achieved around 12 years of age for girls and 14 for boys,<sup>12</sup> and maturity offset is the distance, in years, from peak height velocity. Puberty is a crucial time to assess the proximal patellar tendon attachment as tendon tissue must also mature by the end of puberty as tendon collagen has been shown to be relatively inert after age 17.<sup>13</sup> Understanding the normal maturative process of the proximal patellar tendon is critical, as disrupting this process may lead to the development of pathology and symptoms, as has been shown at the distal attachment.<sup>14,15</sup>

Little research has looked at the maturation of the patellar tendon and the formation of the proximal and distal patellar tendon attachments. Ducher et al looked at the distal attachment of the patellar tendon to the tibia during adolescence and showed mature attachments formed on average 2 years after PHV in tennis players.<sup>14,15</sup> Disruption to normal distal tendon development at this critical stage of maturation has been associated with pain (Osgood-Schlatter disease).<sup>16</sup> To investigate whether disruption of the normal development of the proximal tendon leads to pain, a clear understanding of the formation of a mature proximal patellar tendon attachment during adolescence is critical.

Tendon maturation can be measured by quantifying tendon thickness using conventional grayscale ultrasound. Patellar tendon thickness has been positively correlated with age in 11- to 15-year-old volleyball players.<sup>17</sup> However, the effect of puberty is unclear as no significant difference in patellar tendon thickness was found in prepubertal vs postpubertal 13-year-old athletes.<sup>18</sup> Mechanically, Achilles tendon stiffness was greater for post-PHV adolescent males compared to a pre-PHV group.<sup>19</sup> In a cross-sectional study, the proximal tendon attachment in participants who were less than 1 year post-peak height velocity had variable appearance on grayscale ultrasound, while those who were more than 1 year post-PHV had a grayscale appearance similar to mature participants between 21 and 40 years of age.<sup>20</sup> These findings suggest that the period around peak height is critical in the formation of an organized and mature tendon attachment. A limitation of some of these previous studies was that they relied on subjective measures of tendon structure, where new imaging modalities allowing for quantification of structure may provide further insight and objectivity.

Ultrasound tissue characterization (UTC) is an ultrasound-based imaging modality, which has been used to investigate the clinical presentation of tendinopathy, but has also provided insight into subtle changes in response that have previously not been detected by conventional imaging.<sup>21,22</sup> Based on the consistency of the grayscale image along the length of the tendon, four echotypes are generated that can be quantified as a percentage. These echotypes have been validated and shown to discriminate between different pathological states,<sup>23,24</sup> as well as exhibit excellent interobserver reliability<sup>24</sup> and intraobserver reliability.<sup>25</sup> UTC may be a useful tool in investigating the maturation of the tendon, as it does not rely on subjective interpretation.

The aim of this longitudinal study was to observe the proximal patellar tendon development during the adolescent growth spurt in healthy ballet dancers and to determine the effect of maturity offset on the tendon over time. Ballet dancers were selected because they have a high jumping volume in their sport, which loads the patellar tendon, and they have a low attrition rate, which allowed for follow-up over a 2-year period. The hypothesis was that the proximal patellar tendon would transition toward a mature appearance, thickness, and composition during the adolescent growth spurt.

## 2 | METHODS

Ballet students from the Australian Ballet School and Victorian College of the Arts Secondary School (11-18 years of age at the start) participated in this study. Maturity at baseline varied from prepubertal to postpubertal, and postpubertal participants were included to examine whether change in tendon structure occurred after puberty. All participants were regularly involved in 4-8 hours of daily dance classes. A typical 1.5-hours ballet class can include 200 jumps.<sup>26</sup> Data were collected every 6 months for 2 years, five time points in total. As this study aims at investigating normal tendon maturation, dancers exhibiting tendon pathology (indicated by the presence of a hypochoic area at more than one data collection point) were excluded. Knee pain was not considered as this study was primarily focused on the structure of the tendon during puberty. Monash University's Ethics Committee approved this study, and all participants, or if aged under 16 years the participants' parents, gave informed consent.

### 2.1 | Anthropometric measurements

Height (cm) and sitting height (cm) were measured with a stadiometer, and weight using electronic scales (kg) was collected at each data point. Sitting height was measured with participants sitting tall on a table, thighs fully supported on the table and feet supported with knees flexed to 90°. The measurement of sitting height was taken from the ischial

tuberosity to the top of the participant's head. Leg length was calculated by subtracting sitting height from the standing height. The interaction between leg length and trunk growth rate changes during the adolescent growth spurt and can be estimated with peak height velocity (PHV).<sup>12</sup> Maturity offset is calculated based on the equation by Mirwald, et al and is the number of years a person is away from his PHV.<sup>12</sup> Participants were categorized as either pre- or post-peak height velocity if their maturity offset was negative or positive at baseline, respectively.

## 2.2 | Ultrasound tissue characterization

Ultrasound tissue characterization (UTC) scans were performed on each participant's left knee, which was flexed to 90° while the participant was in a supine position. Scans were conducted by one of the two investigators (AR or SD). The students were scanned in the middle of dance classes each time, which helped to ensure consistency with any possible subtle effects of exercise on tendon structure.<sup>27</sup> A linear array ultrasound transducer (SmartProbe 10L5, Terason 2000+; Teratech) mounted in a tracking device with a built-in acoustic-coupling standoff pad (UTC Tracker, UTC Imaging) was placed on the patellar tendon. Once a clear image of the tendon and inferior pole was apparent, the transducer moved automatically distally over the length of the tendon capturing 600 transverse grayscale image every 0.2 mm.

UTC software utilized these 600 contiguous transverse ultrasound images to render a three-dimensional grayscale image.<sup>23</sup> The dedicated software analyzes the stability of the echopattern across multiple transverse images categorizing the tendon into four echotypes (UTC2010, UTC Imaging): echotype I (green) is the most stable, echotype II (blue) is stable but slightly less organized than type I, echotype III (red) is slightly disorganized, and echotype IV (black) is the most disorganized.<sup>23,24,27</sup> Histopathological specimens from the horse have been correlated with UTC echotypes to show it is a valid modality to estimate pathology.<sup>23</sup> UTC also demonstrates excellent inter- and intraobserver reliability with ICC of 0.95 for determining echotypes I and II.<sup>24</sup>

The region of interest (ROI) for the patellar tendon was selected from the disappearance of the inferior pole of the patella, extending 2 cm distally. Manually selected contours were placed along the length of the tendon in intervals no more than 4 mm. The UTC software automatically interpolated contiguous ROIs creating a tendon volume where the proportions of each echotype were calculated (0-1 cm from the inferior pole and 1-2 cm from the inferior pole). Quantification of the UTC echotype was performed by the same investigator (AR) blinded to participants' identity and age, with the window size set at 25 (slice thickness 4.8 mm). Contours were reviewed by another trained researcher (SD) to ensure consistency.

## 2.3 | Grayscale score

A classification system developed to categorize the appearance of normal tendon attachments on grayscale imaging was based on grayscale imaging features at different maturity levels in the sagittal, transverse, and coronal planes.<sup>20</sup> The tendon was scored between 0 and 2 based on the appearance in each of the three planes, where tendon fibers were classified as either clearly not attached to the patellar (score 0), through to clearly attached (score 2). The total grayscale score is between 0 and 6, where 0 represents an immature tendon appearance and 6 represents a fully mature tendon appearance.

## 2.4 | Anterior-posterior thickness

Anterior-posterior thickness (mm) was measured in the axial plane using the grayscale ultrasound images on the UTC. Measurements were taken at the inferior pole of the patella, 1 and 2 cm distal. Changes in the AP thickness may vary over the length of the tendon {Coupe, 2008 #2399}; therefore, it was important not only to capture changes over time in the proximal tendon but also to show any changes in the tendon midportion.

## 2.5 | Statistical analysis

Analyses were carried out using the plm package in the R statistical package. Participants were excluded if they missed more than two data points, and all missing time points were removed from analyses. Analysis was completed using a random effects multivariate longitudinal data regression model with an interaction term to test whether there was a differential effect of maturity offset on the outcomes of interest: (echopattern by type (I-IV) at 1 and 2 cm distal to the proximal attachment, anterior-posterior thickness at the inferior pole, 1 and 2 cm distal, and grayscale score) after participants reached peak height velocity. The random effects longitudinal model allows the analysis of between and within individual variation of longitudinal data.<sup>28</sup> For this analysis, maturity offset was the independent variable and each of the previously mentioned outcomes was the dependent variables. The purpose of the interaction term was to determine whether maturity offset had a greater marginal effect on the outcomes after the participants had passed peak height velocity. The regression model is as specified in the following equation:

$$y_{it} = \alpha + \beta_1 \text{MaturityOff} + \beta_2 \text{MaturityOff} \times \text{Peak Height} + \epsilon_{it}$$

$y_{it}$  represents the outcome measures of interest,  $\text{MaturityOff}$  is the maturity offset measure (measured in years),  $\text{Peak Height}$  is an indicator variable equal to 1 if the participant is past peak height velocity at the start of the study (16 participants) and 0 otherwise (36 participants), and  $\epsilon_{it}$  represents the idiosyncratic error term. In the equation,  $\beta_1$  represents the

primary effect of maturity offset on the outcome of interest and  $\beta_2$  represents the differential effect of maturity offset if a participant is past peak height velocity. Therefore, the total effect of maturity offset on the outcome of interests for participants past peak height velocity is  $\beta_1 + \beta_2$ .

The effect of sex on outcomes was not specifically tested because of the small numbers; however, the maturity offset calculation is slightly different for males and females, thereby controlling for differences in growth spurt by sex. For the analysis, the evaluator was not blinded to time point. Additionally, to measure the change in grayscale score over time, grayscale score was regressed on time periods relative to the baseline score.

### 3 | RESULTS

Sixty-one participants were recruited for this study, in which 9 were excluded because of the missing data or hypoechoic areas. Of the remaining 52 participated, 32 were women and 20 men, with an age range at baseline 11–18 years. Dancers participated in 10–27 hours of dance class and rehearsal per week, increasing with age. Of the female participants, 24 were pre-PHV at baseline and 8 were post-PHV. Of the 20 male participants, 12 were pre-PHV at baseline.

#### 3.1 | Ultrasound tissue characterization

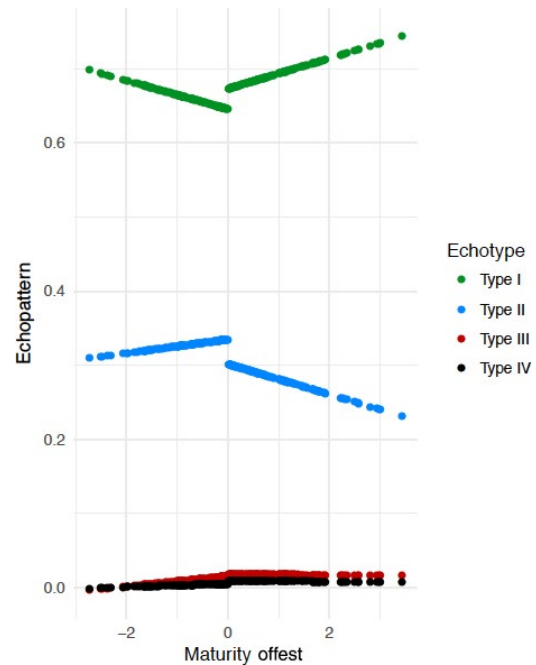
Once participants were post-PHV, maturity offset had a positive relationship with the percentage of echotype I, indicating increases in normal aligned tendon bundles after PHV. There was also a significant relationship between echotype III, representing disorganized fibrillar tissue, and maturity offset on participants post-PHV (Figures 1 and S1). No significant relationship was observed between any echotype and maturity offset beginning prior to PHV. These findings were similar for both the first and second centimeters of the tendon. In both the first and second centimeters, a marginal increase of 4.2% and 4.0% of echotype I was observed after PHV (Tables 1 and S1).

#### 3.2 | Grayscale score

The grayscale score increased as the group transitioned through adolescence, but maturity offset showed no significant effects on the grayscale score (Table S2).

#### 3.3 | Anterior-posterior thickness

Tendon thickness 2 cm distal to the inferior pole was associated with maturity offset, regardless of whether participants were pre- or post-PHV at the start of the study. The tendon thickened at a rate of 2 mm/y in second cm (Table S3). The participants also demonstrated an increased thickness throughout the tendon when they reached peak height velocity (Table S3).



**FIGURE 1** Best-fit line for the predicted value of the effect of maturity offset (*x*-axis) on echopattern (*y*-axis) based on the estimated parameters generated from the interaction effect regression model. The estimated parameters from this model are shown in Table 1 for each echotype in the proximal first centimeter of the tendon. Key: black (type IV), blue (type II), green (type I), and red (type III)

### 4 | DISCUSSION

This study demonstrates a transition toward more stable and mature tendon tissue post-PHV in adolescent jumping athletes with normal patellar tendons. There was a greater marginal effect of maturity offset on the UTC echopattern after peak height velocity, which showed increases in echotype I in the proximal 2 centimeters of the tendon. These UTC changes suggest improvements in tendon structure. These findings are consistent with the hypothesis that maturative structural changes are related to peak height velocity.

Anterior-posterior thickness increased in the patellar tendon during adolescence in the second centimeter of the tendon with maturity offset. Considering that PHV measures the accelerated growth in long bones of the lower limb, it is consistent that after this growth spurt, the patellar tendon would thicken. The findings in this longitudinal study are consistent with a previous cross-sectional study<sup>20</sup> and a longitudinal study that found patellar tendon hypertrophy was associated with late adolescence<sup>10</sup>; however, it is inconsistent with another study, which found no change in patellar tendon thickness in asymptomatic tendons over adolescence<sup>5</sup> although participants were already 15–16 years of age at the start of that study. Increasing tendon thickness may be an adaptive mechanism to cope with the sudden increase in femur length and muscle mass that increases tensile loading on the tendon.

A previous cross-sectional study found grayscale scores varied in the pre- and peri-peak height velocity participants, while post-PHV participants had subjective features of a mature tendon attachment.<sup>20</sup> Interestingly, this longitudinal study showed that there was no relationship between grayscale score and maturity offset.

Peak height velocity and the adolescent growth period is a critical time for changes within tendon structure and thickness. This study supports the concept of tendon maturation occurring after peak height velocity, before tendon collagen turnover is limited around age 17.<sup>13</sup> Because tendons that appear normal by age 17 are at a low risk for developing pathology or symptoms later in life,<sup>29</sup> this maturation process after PHV is an important developmental stage for ballet dancers and potentially other jumping athletes. There is potential to use these data for managing load on adolescent tendons, where key periods of tendon development are identified through measures of puberty and jumping loads managed to ensure normal tendon development.

Ensuring healthy and normal tendon development in adolescent athletes requires identification of when these changes occur. This study supports the hypothesis that the adolescent growth spurt is the critical transition phase in proximal patellar tendon maturation. Our findings at the proximal patellar tendon attachment are consistent with the findings at the distal patellar tendon attachment, which showed a transition to a mature attachment 2 years after peak height velocity.<sup>14,15</sup> To promote developing optimal tendon structure, future research must investigate factors that contribute to or inhibit normal tendon development.

## 5 | LIMITATIONS

Some participants in this study were not pre-peak height velocity at the start of the study. Other measures of adolescent

**TABLE 1** The estimated parameters of echopattern change based on maturity offset, peak height velocity, and their interaction generated from the regression model in the proximal first centimeter of the tendon

	Type I (green)	Type II (blue)	Type III (red)	Type IV (black)
Maturity offset	-0.008 (0.015)	0.001 (0.015)	0.004 (0.003)	0.002 (0.002)
Peak height	-0.006 (0.020)	-0.008 (0.021)	0.009 (0.005)	0.004 (0.002)
Interaction effect	0.042** (0.020)	-0.032 (0.020)	-0.007 (0.004)	-0.003 (0.002)
N	222	222	222	222
R <sup>2</sup>	0.096	0.078	0.049	0.049
Adjusted R <sup>2</sup>	0.084	0.065	0.036	0.035
F statistic (df = 3; 218)	7.749***	6.128***	3.744**	3.709**

\*\*Significant at the 5 percent level.

\*\*\*Significant at the 1 percent level.

growth may be more accurate than PHV; however, methods such as Tanner staging and wrist X-ray are ethically difficult. Accuracy of the Mirwald equation in lower body weight female athletes who may be late to maturity is not known. While other imaging modalities may have been more valid for measures of tendon thickness, one of the key advantages of UTC, aside from the ability to measure exactly the same point in the tendon each time and the control over scanning technique that is better than standard US, is its portability. It would be impractical to get the participants to an imaging facility for repeated MR scans, whereas the UTC was easily brought to the schools for each time point. The minimal detectable change in patellar tendons for a UTC scan was identified as 1.7% of aligned (echotype I+II) and disorganized (echotype III+IV) structure.<sup>30</sup> While the UTC has not been validated in humans, it has been validated in horse tendons, which are similar to human tendons<sup>23,31,32</sup> although it has not specifically been validated for patellar tendon attachments. Additionally, the grayscale score has not yet been validated.

## 6 | PERSPECTIVES

This study adds to the understanding of how and when the proximal patellar tendon matures during adolescence in the athletic population. The period after the adolescent growth spurt is a critical time for the proximal patellar tendon to develop, with changes observed on UTC indicative of improvements in tendon structure. These findings are important for young athletes, coaches, and medical professionals to promote healthy tendon maturation. More research is needed to identify factors that support this normal development or those that can lead to the development of pathology in young jumping athletes.

## ACKNOWLEDGEMENTS

The authors thank Janet Karin of the Australian Ballet School and Margaret Storey of the Victorian College of the Arts Secondary School for their help in coordinating and facilitating data collection. The authors also thank Daniel Brent, PhD, for consulting with statistical analysis. The results of this study are presented clearly, honestly, and without fabrication, falsification, or inappropriate data manipulation and do not constitute endorsement by ACSM.

## CONFLICT OF INTERESTS

There are no conflict of interests of financial disclosures.

## ORCID

A. Rudavsky  <http://orcid.org/0000-0002-5862-9931>

S. Docking  <http://orcid.org/0000-0001-7051-7548>

## REFERENCES

1. Maffulli N, Kahn KM. Clinical nomenclature for tendon injuries. *Med Sci Sports Exerc.* 1999;31:352-353.
2. Simpson M, Rio E, Cook J. At what age do children and adolescents develop lower limb tendon pathology or tendinopathy? a systematic review and meta-analysis. *Sports Med.* 2016;46:545-557.
3. Comin J, Cook JL, Malliaras P, et al. The prevalence and clinical significance of sonographic tendon abnormalities in asymptomatic ballet dancers: a 24-month longitudinal study. *Br J Sports Med.* 2013;47:89-92.
4. Cook JL, Khan KM, Kiss ZS, Purdam CR, Griffiths L. Prospective imaging study of asymptomatic patellar tendinopathy in elite junior basketball players. *J Ultrasound Med.* 2000;19:473-479.
5. Visnes H, Tegnander A, Bahr R. Ultrasound characteristics of the patellar and quadriceps tendons among young elite athletes. *Scand J Med Sci Sports.* 2015;25:205-215.
6. Crawford GN. An experimental study of tendon growth in the rabbit. *J Bone Joint Surg Am.* 1950;32-B:234-243.
7. Elliott DH. Structure and function of mammalian tendon. *Biol Rev Camb Philos Soc.* 1965;40:392-421.
8. Hughes H. An experimental study of the post-natal growth of tendon. *Anat. Anz.* 1956;103:192-197.
9. Mersmann F, Bohm S, Schroll A, Boeth H, Duda G, Arampatzis A. Evidence of imbalanced adaptation between muscle and tendon in adolescent athletes. *Scand J Med Sci Sports.* 2014;24:e283-e289.
10. Mersmann F, Bohm S, Schroll A, Boeth H, Duda GN, Arampatzis A. Muscle and tendon adaptation in adolescent athletes: a longitudinal study. *Scand J Med Sci Sports.* 2017;27:75-82.
11. Mersmann F, Bohm S, Schroll A, Marzilger R, Arampatzis A. Athletic training affects the uniformity of muscle and tendon adaptation during adolescence. *J Appl Physiol (1985).* 2016;121:893-899.
12. Mirwald RL, Baxter-Jones AD, Bailey DA, Beunen GP. An assessment of maturity from anthropometric measurements. *Med Sci Sports Exerc.* 2002;34:689-694. Epub 2002/04/05.
13. Heinemeier KM, Schjerling P, Heinemeier J, Magnusson SP, Kjaer M. Lack of tissue renewal in human adult Achilles tendon is revealed by nuclear bomb (14)C. *FASEB J.* 2013;27:2074-2079.
14. Ducher G, Cook J, Lammers G, et al. The ultrasound appearance of the patellar tendon attachment to the tibia in young athletes is conditional on gender and pubertal stage. *J Sci Med Sport.* 2010;13:20-23.
15. Ducher G, Cook J, Spurrier D, et al. Ultrasound imaging of the patellar tendon attachment to the tibia during puberty: a 12-month follow-up in tennis players. *Scand J Med Sci Sports.* 2010;20:e35-e40.
16. Saily M, Whiteley R, Johnson A. Doppler ultrasound and tibial tuberosity maturation status predicts pain in adolescent male athletes with Osgood-Schlatter's disease: a case series with comparison group and clinical interpretation. *Br J Sports Med.* 2013;47:93-97.
17. Toprak U, Ustuner E, Uyanik S, et al. Comparison of ultrasonographic patellar tendon evaluation methods in elite junior female volleyball players: thickness versus cross-sectional area. *Diagn Interv Radiol.* 2012;18:200-207.
18. Cassel M, Carlsohn A, Frohlich K, John M, Riegels N, Mayer F. Tendon adaptation to sport-specific loading in adolescent athletes. *Int J Sports Med.* 2016;37:159-164.
19. Mogi Y, Torii S, Kawakami Y, Yanai T. A cross-sectional study on the mechanical properties of the Achilles tendon with growth. *Eur J Appl Physiol.* 2018;118:185-194.
20. Rudavsky A, Cook J, Magnusson SP, Kjaer M, Sean D. Characterising the proximal patellar tendon attachment and its relationship to skeletal maturity in adolescent ballet dancers. *Muscles Ligaments Tendons J.* 2017;7:306-314.
21. Docking SI, Rosengarten SD, Daffy J, Cook J. Structural integrity is decreased in both Achilles tendons in people with unilateral Achilles tendinopathy. *J Sci Med Sport.* 2015;18:383-387.
22. Rosengarten SD, Cook JL, Bryant AL, Cordy JT, Daffy J, Docking SI. Australian football players' Achilles tendons respond to game loads within 2 days: an ultrasound tissue characterisation (UTC) study. *Br J Sports Med.* 2015;49:183-187.
23. van Schie HT, Bakker EM, Jonker AM, van Weeren PR. Computerized ultrasonographic tissue characterization of equine superficial digital flexor tendons by means of stability quantification of echo patterns in contiguous transverse ultrasonographic images. *Am J Vet Res.* 2003;64:366-375.
24. van Schie HT, de Vos RJ, de Jonge S, et al. Ultrasonographic tissue characterisation of human Achilles tendons: quantification of tendon structure through a novel non-invasive approach. *Br J Sports Med.* 2010;44:1153-1159.
25. Wezenbeek E, Mahieu N, Willems TM, et al. What does normal tendon structure look like? New insights into tissue characterization in the Achilles tendon. *Scand J Med Sci Sports.* 2017;27:746-753.
26. Liederbach M, Richardson M, Rodriguez M, Compagno J, Dilgen FE, Rose DJ. Jump exposures in the dance training environment: a measure of ergonomic demand. *J Athl Train.* 2006;41:S85.
27. Docking SI, Daffy J, van Schie HT, Cook JL. Tendon structure changes after maximal exercise in the Thoroughbred horse: use of ultrasound tissue characterisation to detect in vivo tendon response. *Vet J.* 2012;194:338-342. Epub 2012/06/05.
28. Laird NM, Ware JH. Random-effects models for longitudinal data. *Biometrics.* 1982;38:963-974.
29. Gisslen K, Gyulai C, Nordstrom P, Alfredson H. Normal clinical and ultrasound findings indicate a low risk to sustain jumper's knee patellar tendinopathy: a longitudinal study on Swedish elite junior volleyball players. *Br J Sports Med.* 2007;41:253-258.
30. Docking SI, Cook J. Pathological tendons maintain sufficient aligned fibrillar structure on ultrasound tissue characterization (UTC). *Scand J Med Sci Sports.* 2016;26:675-683.
31. Patterson-Kane JC, Becker DL, Rich T. The pathogenesis of tendon microdamage in athletes: the horse as a natural model for basic cellular research. *J Comp Pathol.* 2012;147:227-247.
32. Smith RK, Garvican ER, Fortier LA. The current 'state of play' of regenerative medicine in horses: what the horse can tell the human. *Regen Med.* 2014;9:673-685.

## SUPPORTING INFORMATION

Additional supporting information may be found online in the Supporting Information section at the end of the article.

**How to cite this article:** Rudavsky A, Cook J, Docking S. Quantifying proximal patellar tendon changes during adolescence in elite ballet dancers, a 2-year study. *Scand J Med Sci Sports.* 2018;28:2369–2374. <https://doi.org/10.1111/sms.13235>